

## ORIGINAL ARTICLE

# Ultrasound-guided placement of long peripheral cannula in children with cystic fibrosis

Massimiliano Giardina MD, PhD<sup>1</sup> | David Barillà MD<sup>2</sup> | Claudia Crimi MD, PhD<sup>3</sup> |  
Amelia Arone MD<sup>4</sup> | Filippo Benedetto MD, PhD<sup>2</sup> | Cristina Lucanto MD<sup>5</sup> |  
Rossella Natoli MD<sup>6</sup> | Roberto Messina MD, PhD<sup>1</sup> | Antonio David MD<sup>7</sup> |  
Alberto Noto MD, PhD<sup>7</sup>

<sup>1</sup>Division of Anesthesia and Critical Care, A. O. U. Policlinico "G. Martino", Messina, Italy

<sup>2</sup>Department of Biomedical and Dental Sciences and Morphofunctional Imaging, Unit of Vascular Surgery, Policlinico G. Martino, University of Messina, Messina, Italy

<sup>3</sup>Respiratory Medicine Unit, Policlinico "G. Rodolico-San Marco", University Hospital, Catania, Italy

<sup>4</sup>IRCCS Policlinico San Donato, San Donato Milanese, Italy

<sup>5</sup>Regional Centre for Cystic Fibrosis, A. O. U. Policlinico G. Martino, Messina, Italy

<sup>6</sup>School of Medicine and Surgery, University of Milano-Bicocca, Milano, Italy

<sup>7</sup>Department of Human Pathology of the Adult and Evolutive Age "Gaetano Barresi", Division of Anesthesia and Critical Care, University of Messina, Messina, Italy

## Correspondence

Alberto Noto, MD, PhD, Department of Human Pathology of the Adult and Evolutive Age "Gaetano Barresi," Division of Anesthesia and Critical Care, University of Messina, Messina, Italy.

Email: [alberto.noto@unime.it](mailto:alberto.noto@unime.it)

## Abstract

**Background:** The natural history of cystic fibrosis (CF) lung disease is a chronic deterioration of lung function with intermittent episodes of pulmonary infectious exacerbations (PEs). Reliable venous access is a milestone of effective management of such exacerbations, managed both in hospital and outpatient chronic therapy. The aim of our study was to analyze the feasibility of ultrasound-guided positioning of long peripheral catheters (LPC) as reliable midterm venous access in children affected by CF.

**Methods:** In this single-center prospective study, over a 60-month period, we included paediatric CF subjects admitted with PEs and undergoing intravenous antibiotic treatment. LPCs were inserted in all participants by paediatric anaesthesiologists with ultrasound guide technique. Prospective data were collected assessing catheter positioning procedure and complications.

**Results:** A total of 122 LPC insertions were performed in 55 CF children. Participants had a median age of 6.75 years (interquartile range: 3.7–13.5) at the time of catheter insertion. Implantation was successful on the first attempt in 86% of cases; 2 (1%) major insertion-related complications were reported. Eighty-eight percent of catheters were electively removed at the end of antibiotic therapy without any complication. Seven percent of the catheters were removed electively for occlusion and 2% for local dislodgment.

**Conclusions:** The results of the present study suggest that ultrasound-guided positioning of LPCs are safe alternative means of peripheral venous access in children with chronic diseases such as CF.

## KEYWORDS

antibiotic therapy, cystic fibrosis, ultrasound, vascular access

## 1 | INTRODUCTION

Cystic fibrosis (CF) is the most common genetic disorder in white individuals, caused by mutations of the CF transmembrane conductance regulator, and it is well known to be associated with chronic airways mucus obstruction, inflammation, and infections leading to a progressive decline of pulmonary function and lung damage.<sup>1</sup>

Although CF is a multiorgan system disease, its effects on the pulmonary system are the leading cause of patient morbidity and mortality.<sup>2</sup> The natural history of CF lung disease is a chronic deterioration of lung function with intermittent episodes of pulmonary infectious exacerbations (PEs). Infectious exacerbations play an important role in children with CF and should be treated promptly to prevent the further progression of lung damage.

Reliable intravenous access is essential for the safe and effective management of in-hospital chronic outpatient therapies. Considerable technological advances have rapidly changed the landscape of vascular access, and a wide variety of minimally invasive medium-term venous access devices (VADs) are available nowadays for vascular access creation during and beyond hospitalization.<sup>3</sup>

The extensive use of targeted antibiotic therapies has contributed significantly to increasing the survival of this population.<sup>4</sup> Although the optimal duration of intravenous antibiotic therapy is not clearly defined, antibiotic treatment is commonly continued until the disappearance of signs and symptoms of PEs: a 2-week period is the usual duration of a course of IV antibiotics.<sup>5</sup> Recently the STOP2 trial<sup>6</sup> showed that among CF adults with less improvement in 1 week, 21-days therapy is not superior to 14-days. However, these findings may not apply to the paediatric population.

Currently, intermittent intravenous antibiotic therapy is delivered via peripherally inserted central catheters (PICCs)<sup>7,8</sup> or midline catheters<sup>9</sup> when peripherally compatible infusion is planned for up to 4 weeks. Nowadays, long peripheral cannulas (LPC), defined (in adults) as devices longer than 6 cm and less than 15 cm, are an alternative intravenous device to administer short term peripherally compatible therapies. These vascular devices can be cheaper and quicker to insert as alternatives to PICCs and midlines; the key technical difference is the positioning in a superficial vein with a direct seldinger technique (catheter-over-guidewire, as described for arterial catheterization).<sup>10</sup> Recently LPC has become particularly popular in subjects with difficult intravenous access, and it is well stated that LPCs could reduce the number of catheters required in patients receiving 7–28 days of IV therapy and decrease the incidence of catheter-related complications.<sup>11,12</sup>

Children very often have poor venous access and repeated IV insertion attempts might be a challenging, unpleasant, frightening, painful, and stressful experience that has a long-lasting impact on children<sup>13</sup> and may negatively affect subsequent medical visits.

We hypothesized that ultrasound-guided positioning of LPC in a deep vein of the upper arm might be an effective and well-tolerated strategy for venous access in CF subjects. Therefore, we performed a prospective observational study to analyze the feasibility of LPC as midterm venous access in children affected by CF.

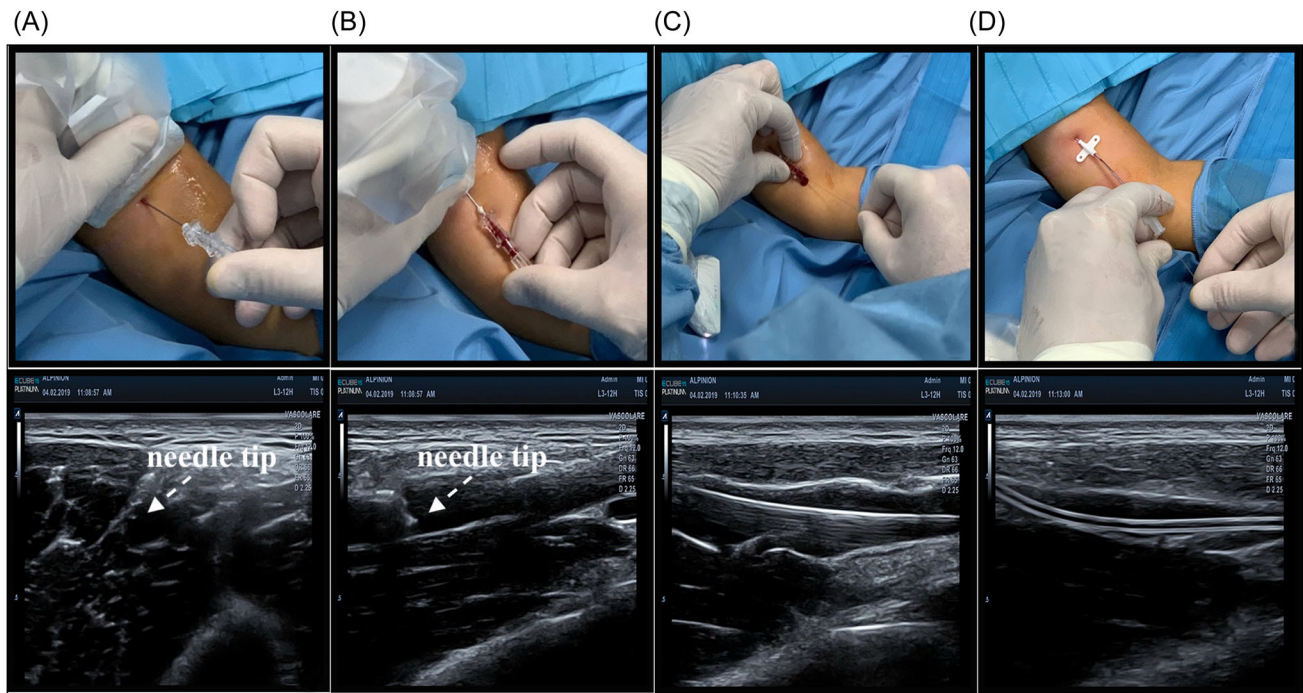
## 2 | MATERIALS AND METHODS

All paediatric CF subjects admitted to the Policlinico G. Martino University Hospital in Messina, Italy, with moderate to severe lung exacerbations and need for intravenous antibiotic treatment were prospectively recruited to position an LPC between June 2014 and June 2019. The study was approved as a quality improvement activity by the Policlinico Universitario G. Martino Health Human Research Ethics Committee (protocol number 123/19).

Polyurethane (Leaderflex; Vygon®; Lf) or polyethylene catheters (Leadcath; Vygon®; Lc) of various sizes (2–3 Fr) and lengths (4, 6, 8 cm) were inserted in all subjects according to the following protocol for Long Intravenous Catheter Insertion. All children under 6 years were sedated. Before catheter placement, both arms were examined by ultrasound to locate the most appropriate vein to cannulate in terms of position and catheter diameter. An ultrasound device with a 10–14 MHz linear probe, 2.5–3 cm large, is commonly used. Upper mid-arm veins are preferred in the following order: basilic, brachial, and cephalic. In the occurrence of subjects with more than one catheter positioned, we changed the target arm if an appropriate vein existed. The tourniquet was placed very close to the axilla. The puncture site was scrubbed with 2% chlorhexidine and was protected by a sterile drape. The probe was covered with sterile wrap. Local anesthesia (0.5–1 ml of 2% lidocaine) was administered with an insulin syringe. Before the venipuncture, the needle was capped with a cap of an abbocath. Venipuncture was performed under direct ultrasound guidance (Figure 1) using an aseptic direct seldinger technique. Insertions were performed by paediatric anaesthesiologists. All catheters were flushed with heparin solution (20 U/2 ml) after each use.

## 3 | DATA AND OUTCOMES

Data were prospectively collected. We recorded patient demographics (age gender), procedure type, insertion site (basilic, brachial, cephalic, or other veins), success at insertion, number of attempts before insertion, duration of the access, and all complications related to LPC. Vein thrombosis, catheter-related infection (CRI), nerve, and arterial puncture were defined as major complications, the latter defined as minor included: catheter break, catheter occlusion, impossible blood withdrawal, phlebitis, medical adhesive-related skin injury, any catheter malfunction, and catheter dislodgement. Complications were evaluated through medical record note descriptions or family telephonic interviews. Unintentional or accidental removal of an LPC was considered as catheter dislodgement. CRI was defined as a clinically suspected catheter infection that required treatment based on clinical judgment and regardless of culture-proven infection. Breakage complications were considered when any component of the LPC apparatus, such as the hub, was cracked or broken. Participants with no complications after insertion of LPC with lower lung symptoms continued their intravenous therapy at home (Table 1).



**FIGURE 1** Technique of LPC placement. (A) Vein visualization in short axis and out-of-plane puncture. (B) Probe rotation and cannulation of the vein in long axis. (C) Guidewire insertion and positioning check with long axis visualization. (D) Catheter advancing into the vein over the guidewire. LPC, long peripheral catheters.

We conducted a sub-group analysis dividing the population into two groups according to age (<6 year old, >6 year old). The Shapiro-Wilk test and histograms visualization was used to analyze variables distribution. The non-normal distribution data was assessed with Mann-Whitney test and presented by the median and percentiles (25th–75th). The data with a normal distribution was assessed with the Student *t*-test. Categorical variables were presented by numbers and percentages analyzed with the use of the  $\chi^2$  test or Fisher exact test, as appropriate. A  $p < 0.05$  was considered significant. All statistical analyses were performed using the SPSS statistical package (IBM SPSS Statistics for Windows; Version 24.0.; IBM Corp.) (Table 2).

## 4 | RESULTS

All subjects ( $N = 55$ ) between 2014 and 2019 were scheduled for LPC positioning. A total of 122 LPC were inserted. Subjects had a median age of 6.75 years (interquartile range: 3.7–13.5) at the time of catheter insertion (Table 1). We inserted 30 Leadercath (24.5%) and 92 Leaderflex (75.5%) (Table 2). In subjects under the age of 6 years, 56 catheters (38 Leadercath, 18 Leaderflex) were positioned. Most catheters were inserted in the upper arm ( $n = 116$ , 95%) and few in the forearm ( $n = 6$ , 5%; all in the cephalic vein). The venipuncture sites in the upper arm are presented in Table 3. Implantation was mainly successful on the first attempt (86%,  $n = 106$ ), with a minority requiring more venipuncture (13%,  $n = 16$ ) (Table 3).

Two major insertion-related complications were reported only in the >6 year old group (Table 4). Most catheters were electively

removed after 14 days at the end of the course of antibiotic therapy without any complication (Table 4). In our prospective cohort study, a full course of 14-days outpatient treatment was completed through an LPC in most subjects without the need for any other vascular access procedures (younger than 6 years old: 83.9%; older than 6 years old: 92.4%). In nine cases, the catheter was removed electively for occlusion and in three cases for local dislodgment. Blood withdrawal was difficult in 65% of catheters. In two cases, we recorded the catheter break (Table 4).

## 5 | DISCUSSION

The present study demonstrated that ultrasound-guided LPCs could be a safe and effective alternative for peripheral venous access in children with CF undergoing antibiotic treatment for PEx; this approach may reduce the number of venipunctures in this population, decreasing their stress, and discomfort. In our population, most subjects (88%) completed the 14-days period of foreseen outpatient treatment through an LPC with no need for further vascular access procedures.

To the best of our knowledge, this is the first large study where LPCs are positioned by ultrasound guidance for midterm antibiotic therapy in CF subjects. Previous studies reported the use of LPCs mainly in acute settings, including emergencies, intensive care, and surgical units.<sup>11,14–16</sup> The administration of a midterm course of antibiotics (>5 days) could be a valid indication for PICCs insertion<sup>17</sup>; however, concerns for their inappropriate use<sup>18</sup> and high rates of

**TABLE 1** Demographics characteristic

	All (N = 122)	<6 year old (N = 56)	>6 year old (N = 66)	p
Sex, n (%)				
Male	42 (34%)	15 (26.8)	27 (40.9)	0.09
Age, median (IQR), year	6.75 (3.5–7.13)	3.41 (2.3–5.1)	12.3 (9.5–15.1)	<0.01
Weight, median (IQR), kg	22.5 (14.1–41.8)	14 (10–16)	41 (29–46)	<0.01
Height, median (IQR), cm	120 (94–150)	93.7 (87–101)	150 (125–157)	<0.01
Genetic mutations, n				0.07
4016insT/R117H	1	1		
F508del/2183 AA- > G	3	3		
F508del/31201GA	2		2	
F508del/384910kbCT	3		3	
F508del/CFTRdele2,3	4	1	3	
F508del/D110E	1		1	
F508del/F508del	35	18	17	
F508del/frameshift exon 14	1		1	
F508del/G1244E	2	1	1	
F508del/G542X	5	3	2	
F508del/L1065P	2		2	
F508del/L1077P	1		1	
F508del/N1303K	20	11	9	
F508del/W1282X	1	1		
G542X/G542X	9	3	6	
G542X/R1158X	3		3	
N1303K/1259insA	4		4	
N1303K/D192G	1	1		
R1066C/L1077P	2	1	1	
R553X/CFTRdele2,3	4		4	
R709X/7113A->G	1	1		

Abbreviation: IQR, interquartile range.

complications<sup>19</sup> have produced looking for safer alternatives.<sup>20</sup> The long lifespan of an LPC is one of the main advantages of these VADs as it keeps a low rate (0.6%) of CRIs.<sup>21</sup>

In the first year, two catheter breaks occurred. We then began to use catheter extension routinely and no further cases were recorded in the following 3 years.

The main advantage of the ultrasound-guided placement of LPC is the fast and successful insertion and the low risk of catheter failure. They can be placed in most veins through a direct seldinger technique; we believe that this technique could be less traumatic for tissues and the vein wall. Conversely, conventional long lines are introduced via a larger 20 G peel-away sheath (indirect seldinger technique). This is an important factor to consider since injection-induced anxiety and procedural pain are the most frequent adverse

effect of venipuncture experienced by children.<sup>22,23</sup> Indeed, cannulation can also be a challenging and time-consuming procedure. The presence of smaller veins combined with increased adiposity and patient anxiety complicate the identification of veins and multiple attempts may be necessary even for the experienced operators<sup>24</sup>; in light of this evidence, the ultrasound-guided positioning could improve the children and parents satisfaction. We should also note that in this study, were infused some antibiotics with a potential risk of thrombophlebitis like vancomycin, imipenem, or amikacin.

Sedation is frequently used in the paediatric population to minimize discomfort and/or pain which may be associated with different kinds of procedures. Although venipuncture is a minimally invasive procedure, it can cause complications and discomfort in a paediatric population. Therefore, all the subjects under the age of 6

**TABLE 2** Catheter type

	All (N = 122)	<6 year old (N = 56)	>6 year old (N = 66)	p
Catheter type, n (%)				
Leadercath	30 (24.6%)	18 (32.1)	12 (18.2)	0.07
Leaderflex	92 (75.4%)	38 (67.9)	54 (81.8)	
French, n (%)				
2 Fr	55 (45.1%)	38 (67.9)	17 (25.8)	
3 Fr	67 (54.9%)	18 (32.1)	49 (74.2)	<0.01
Length, n (%)				
4 cm	29 (23.8%)	29 (51.8)	0 (0)	
6 cm	37 (30.3%)	14 (25)	23 (34.8)	
8 cm	56 (45.9%)	13 (23.2)	43 (65.2)	<0.01

**TABLE 3** Procedures characteristics

	All (N = 122)	<6 year old (N = 56)	>6 year old (N = 66)	p
Arm side, n (%)				
Right	61 (50%)	31 (54.4)	30 (45.5)	
Left	61 (50%)	25 (44.6)	36 (54.5)	0.38
Upper arm zone, n (%)				
Middle third	113 (92.6%)	51 (91.1)	62 (93.9)	
Proximal third	3 (2.4%)	1 (1.8)	2 (3)	
Distal third	1 (0.8%)	0 (0)	1 (1.5)	
Forearm	5 (4.1%)	4 (7.1)	1 (1.5)	0.33
Target vein, n (%)				
Basilic	70 (57.3%)	32 (57.1)	38 (57.6)	
Brachial	43 (35.2%)	18 (32.1)	25 (37.9)	
Cephalic	9 (7.4%)	6 (10.7)	25 (37.9)	0.84
Failed attempt, n (%)				
0	106 (86.9%)	42 (75)	64 (97)	
1	12 (9.8%)	10 (17.9)	2 (3)	
2	4 (3.3%)	4 (7.1)	0 (0)	0.16
Pharmacological sedation, n (%)	55 (45%)	55 (98.2)	0 (0)	<0.01

were sedated (Alogenated vapors) before performing local anesthesia in the site of puncture (Lidocaine 2%, 0.1–0.2 ml). Indeed, we believe that the combination of the two techniques practised alongside would be the most favorable to reduce postprocedural stress and discomfort, as suggested by current practices.<sup>25</sup>

From this point of view, the need for repeated cannulation attempts increases young subjects' discomfort. A recently

**TABLE 4** Complications

	ALL (N = 122)	<6 year old (N = 56)	>6 year old (N = 66)	p
Duration, n (%)				
<7 day	3 (2.4%)	3 (5.4)	0 (0)	
7–13 day	11 (9%)	6 (10.7)	5 (7.6)	
14 day	108 (88%)	47 (83.9)	61 (92.4)	0.12
Phlebitis, n (%)	2 (1.6%)	2 (3.6)	0 (0)	0.12
Vein thrombosis, n (%)	1 (0.8%)	0 (0)	1 (1.5)	0.33
Nerve puncture, n (%)	0	0 (0)	0 (0)	-
Catheter break, n (%)	2 (1.6%)	0 (0)	2 (3.0)	0.19
Arterial puncture, n (%)	1 (0.8%)	0 (0)	1 (1.5)	0.33
Catheter infection, n (%)	0	0 (0)	0 (0)	-
MARSI, n (%)	3 (2.4%)	2 (3.6)	1 (1.5)	0.46
Impossible blood withdrawal, n (%)	79 (64.7%)	56 (100)	23 (34.8)	<0.01
Vascular access lost, n (%)	12 (9.8%)	9 (16.1)	3 (4.5)	
Vascular access lost, n (%)				
Dislodgment	3 (2.4%)	3 (5.4)	0 (0)	
Occlusion	9 (7.3%)	6 (10.7)	3 (4.5)	<0.01

Abbreviation: MARSI, medical adhesive-related skin injury.

published<sup>26</sup> study on a sample of 163 venous catheterizations in a paediatric intensive care unit (both PVCs and PICCs) reported only 38.7% successful venipuncture on the first attempt. Conversely, LPCs are useful as a medium-term intravenous infusion means as most participants can complete their therapeutic scheme without the need for further cannulations in that period.<sup>11</sup>

The feasibility and usefulness of LPCs were already investigated in 2014 using Vygon Leaderflex 22 G 8 cm catheters in children affected by CF.<sup>15</sup> Despite the low number of subjects (20) and the high rate of minor local complications (33%), the mean catheters life (10.8 days), the percentage of subjects who completed the treatment, and the absence of serious adverse events highlighted the safety of this approach as an alternative to other venous accesses. Reproducibility and repeatability of this approach during the years, with a low rate of discomfort for the subjects, represents an advantage to be considered compared with other mid- or long-term accesses and the cost-effectiveness. Our study states that the most frequent complication is the impossibility to draw blood from catheters. This event occurred in all subjects in the <6 year old group, this is certainly correlated with the catheter lumen size (2 Fr: 89% [49/55] vs. 3 Fr: 44% [30/67]  $p < 0.001$ ) and probably with also a suboptimal vein to catheter ratio. We should consider that this complication correlated to the collapse of a small catheter is



common also with PICC (unavailable < 3 Fr) and with epicutaneous cava catheters.

Peripheral venous cannulation of longer duration is costly and time-consuming,<sup>27</sup> and younger age is a well-known risk factor for intravenous catheter failure.<sup>28,29</sup>

In light of these considerations, other kinds of vascular accesses would be advised. The Vygon Leaderflex LPC catheter costs approximately \$40 AUD, while a standard PICC may cost up to \$150 AUD.<sup>15</sup> LPC use for midterm therapy might be a cost-effective solution, compared to peripheral venous cannulation and also comparing PICCs.

In summary, our study on a large cohort of children affected by CF and PEx demonstrates that the use of LPC is an effective and safe option and may represent a valid alternative to PICC in the outpatient treatment of this fragile paediatric population.

## AUTHOR CONTRIBUTIONS

**Massimiliano Giardina:** Conceptualization; formal analysis; investigation; data curation; writing—original; writing—review & editing. **David Barillà:** Data curation; writing—original; writing—review & editing. **Claudia Crimi:** Data curation; writing—original; writing—review & editing. **Arone Amelia:** Investigation; data curation; writing—review & editing. **Filippo Benedetto:** Resources; writing—review & editing; supervision. **Cristina Lucanto:** Resources; writing—review & editing. **Rossella Natoli:** Investigation; data curation; writing—review & editing. **Roberto Messina:** Formal analysis; investigation; writing—review & editing. **Antonio David:** Resources; writing—review & editing; supervision. **Alberto Noto:** Methodology; formal analysis; writing—original; writing—review & editing; supervision; project administration.

## ACKNOWLEDGMENTS

This study did not receive any specific grant from funding agencies in the public, commercial, or not-for-profit sectors. Open Access Funding provided by Università degli Studi di Messina within the CRUI-CARE Agreement.

## CONFLICT OF INTEREST

The authors declare no conflict of interest.

## DATA AVAILABILITY STATEMENT

Data are available on request due to privacy/ethical restrictions.

## REFERENCES

- Knowles MR, Durie PR. What is cystic fibrosis? *N Engl J Med*. 2002;347(6):439-442.
- Cohen-Cymerknoh M, Shoseyov D, Kerem E. Managing cystic fibrosis. *Am J Respir Crit Care Med*. 2011;183(11):1463-1471.
- Bahous G, Salajegheh P, Anari AM, Eshghi A, Aski BH. A review of peripherally inserted central catheters and various types of vascular access in very small children and pediatric patients and their potential complications. *J Med Life*. 2021;14(3):298-309.
- Blanchard AC, Waters VJ. Microbiology of cystic fibrosis airway disease. *Semin Respir Crit Care Med*. 2019;40(06):727-736.
- Abbott L, Plummer A, Hoo ZH, Wildman M. Duration of intravenous antibiotic therapy in people with cystic fibrosis. *Cochrane Database Syst Rev*. 2019;2019(9).
- Goss CH, Heltshe SL, West NE, et al. A randomized clinical trial of antimicrobial duration for cystic fibrosis pulmonary exacerbation treatment. *Am J Respir Crit Care Med*. 2021;204(11):1295-1305.
- Ullman AJ, Bernstein SJ, Brown E, et al. The Michigan appropriateness guide for intravenous catheters in pediatrics: miniMAGIC. *Pediatrics*. 2020;145(suppl\_3):S269-S284.
- Sharp R, Esterman A, McCutcheon H, Hearse N, Cummings M. The safety and efficacy of midlines compared to peripherally inserted central catheters for adult cystic fibrosis patients: a retrospective, observational study. *Int J Nurs Stud*. 2014;51(5):694-702.
- Kleidon TM, Schults JA, Wainwright C, et al. Comparison of midline catheters and peripherally inserted central catheters to reduce the need for general anesthesia in children with respiratory disease: a feasibility randomized controlled trial. *Pediatric Anesthesia*. 2021;31(9):985-995.
- Higgs Z, Macafee D, Braithwaite B, Maxwell-Armstrong C. The Seldinger technique: 50 years on. *Lancet*. 2005;366(9494):1407-1409.
- Pacilli M, Bradshaw CJ, Clarke SA. Use of 8-cm 22G-long peripheral cannulas in pediatric patients. *J Vasc Access*. 2018;19(5):496-500.
- Qin KR, Ensor N, Barnes R, Englin A, Nataraja RM, Pacilli M. Long peripheral catheters for intravenous access in adults and children: a systematic review of the literature. *J Vasc Access*. 2021;22(5):767-777.
- Bijttebier P, Vertommen H. The impact of previous experience on children's reactions to venepunctures. *J Health Psychol*. 1998;3(1):39-46.
- Morosini I, Lucenti E, Mozzarelli F, Raffo E. Mini-midline a new device for peripheral venous catheterization UN emergency wards. *J Anest & Inten Care Med*. 2018;6(1):555-678. doi:10.19080/JAICM.2018.06.555678
- Qian SY, Horn MT, Barnes R, Armstrong D. The use of 8-cm 22G seldinger catheters for intravenous access in children with cystic fibrosis. *J Vasc Access*. 2014;15(5):415-417.
- Paladini A, Chiaretti A, Sellasie KW, Pittiruti M, Vento G. Ultrasound-guided placement of long peripheral cannulas in children over the age of 10 years admitted to the emergency department: a pilot study. *BMJ Paediatr Open*. 2018;2(1):e000244.
- Vaughn VM, O'Malley M, Flanders SA, et al. Association of infectious disease physician approval of peripherally inserted central catheter with appropriateness and complications. *JAMA Netw Open*. 2020;3(10):e2017659.
- Chopra V, Smith S, Swaminathan L, et al. Variations in peripherally inserted central catheter use and outcomes in Michigan hospitals. *JAMA Intern Med*. 2016;176(4):548-551.
- Noonan PJ, Hanson SJ, Simpson PM, Dasgupta M, Petersen TL. Comparison of complication rates of central venous catheters versus peripherally inserted central venous catheters in pediatric patients\*. *Pediatr Crit Care Med*. 2018;19(12):1097-1105.
- Burek AG, Parker J, Bentzien R, Talbert L, Havas M, Hanson SJ. The development of a long peripheral catheter program at a large Pediatric Academic Center: a pilot study. *Hosp Pediatr*. 2020;10(10):897-901.
- Patel SA, Araujo T, Rodriguez LP, Sanchez CR, Snyder A, Chopra V. Long peripheral catheters: a retrospective review of major complications. *J Hosp Med*. 2019;14(12):758-760.
- McMurtry CM, Pillai Riddell R, Taddio A, et al. Far from "Just a Poke": common painful needle procedures and the development of needle fear. *Clin J Pain*. 2015;31(suppl 10):S3-S11.
- Cummings EA, Reid GJ, Finley AG, McGrath PJ, Ritchie JA. Prevalence and source of pain in pediatric inpatients. *Pain*. 1996;68(1):25-31.
- Reigart JR, Chamberlain KH, Eldridge D, et al. Peripheral intravenous access in pediatric inpatients. *Clin Pediatr*. 2012;51(5):468-472.

25. Sahyoun C, Cantais A, Gervais A, et al. Pediatric procedural sedation and analgesia in the emergency department: surveying the current European practice. *Eur J Pediatr*. 2021;180(6):1799-1813.
26. de la Vieja-Soriano M, Blanco-Daza M, Macip-Belmonte S, Dominguez-Muñoz M, López-Sánchez E, Pérez-Pérez E. Difficult intravenous access in a paediatric intensive care unit. *Enferm Intensiva*. 2021; S1130-2399(21):00057-2. doi:10.1016/j.enfi.2021.03.007
27. Tandale SR, Dave N, Garasia M, Patil S, Parelkar S. A study of morbidity and cost of peripheral venous cannulation in neonates admitted to paediatric surgical intensive care unit. *J Clin Diagn Res*. 2017; 11(3):UC08-UC10. doi:10.7860/JCDR/2017/23600.9570
28. Unbeck M, Förberg U, Ygge B-M, Ehrenberg A, Petzold M, Johansson E. Peripheral venous catheter related complications are common among paediatric and neonatal patients. *Acta Paediatr*. 2015;104(6):566-574.
29. Fonzo-Christe C, Parron A, Combescore C, Rimensberger P, Pfister R, Bonnabry P. Younger age and in situ duration of peripheral intravenous catheters were risk factors for extravasation in a retrospective paediatric study. *Acta paediatrica*. 2018;107(7): 1240-1246.

**How to cite this article:** Giardina M, Barillà D, Crimi C, et al. Ultrasound-guided placement of long peripheral cannula in children with cystic fibrosis. *Pediatric Pulmonology*. 2022;57:2060-2066. doi:10.1002/ppul.25978