

Incidence and Factors Influencing Retinal Displacement in Eyes Treated for Rhegmatogenous Retinal Detachment With Vitrectomy and Gas or Silicone Oil

Roberto dell'Omo,^{1,2} Andrea Scupola,³ Davide Viggiano,¹ Maria Grazia Sammarco,³ Serena De Turris,¹ Mario R. Romano,⁴ Gabriela Grimaldi,³ Ermanno dell'Omo,² and Ciro Costagliola^{1,2}

¹Department of Medicine and Health Sciences "V. Tiberio", University of Molise, Campobasso, Italy

²Eye Clinic "Villa Maria," Campobasso, Italy

³Department of Ophthalmology, Catholic University of Sacred Heart, Rome, Italy

⁴Department of Biomedical Sciences, Humanitas University, Milan, Italy

Correspondence: Roberto dell'Omo, Department of Medicine and Health Sciences "V. Tiberio", University of Molise, Via Francesco De Sanctis 1, 86100 Campobasso, Italy; roberto.dellomo@unimol.it.

Submitted: January 11, 2017

Accepted: June 18, 2017

Citation: dell'Omo R, Scupola A, Viggiano D, et al. Incidence and factors influencing retinal displacement in eyes treated for rhegmatogenous retinal detachment with vitrectomy and gas or silicone oil. *Invest Ophthalmol Vis Sci*. 2017;58:BIO191-BIO199. DOI: 10.1167/iovs.17-21466

PURPOSE. The purpose of this study was to study the incidence and factors influencing retinal displacement in eyes treated for rhegmatogenous retinal detachment (RRD) with pars plana vitrectomy (PPV) and gas or silicone oil.

METHODS. This was a prospective observational case series. One hundred twenty-five eyes with macula-off RRD from 125 patients underwent 25-gauge PPV at two vitreoretinal institutional practices. Eyes without proliferative vitreoretinopathy (PVR) or PVR grade A were tamponated with sulfur hexafluoride (SF6) gas, whereas eyes with PVR grade B received 1000 centistokes silicone oil (SO). The patients postured face-down immediately after surgery. Blue-fundus autofluorescence (B-FAF) pictures were obtained at each follow-up examination. Main outcome measures were incidence and direction of retinal displacement.

RESULTS. Ninety-seven eyes (77.6%) were tamponated with SF6 and 28 eyes (22.4%) with SO. After retinal reattachment, displacement was observed in 44 of 125 (35.2%) eyes (40 eyes in the SF6 group and 4 eyes in the SO group, respectively). The type of tamponade, specifically gas, was the only significant predictor of retinal displacement ($P = 0.007$). The displacement was downward in 39 (88.6%) eyes (36 tamponated with SF6 and 3 with SO) and upward in 5 (11.4%) eyes (4 tamponated with SF6 and 1 with SO).

CONCLUSIONS. Displacement of the retina after repair of macula-off RRD with PPV is observed using either SF6 gas or SO. Downward and upward displacements may occur with both tamponades, but downward dislocation is more common. Of the factors potentially implicated in favoring displacement that were studied, only the type of tamponade, specifically the gas, was significant.

Keywords: blue fundus autofluorescence, retinal vessel printings, retinal detachment, pars plana vitrectomy, retinal displacement

There has recently been a trend toward pars plana vitrectomy (PPV) as the preferred method for treatment for rhegmatogenous retinal detachment (RRD). The reasons behind this trend include the advent of outpatient ambulatory surgery and improvements in technology, instrumentation, and viewing systems.¹⁻⁵

When PPV is chosen for the treatment of RRD, it is typically accompanied with a postoperative intraocular tamponade agent—most commonly gases or silicone oils (SOs). Many surgeons prefer to use SO for complicated RRD or if postoperative airplane or high elevation travel is planned. However, a recent prospective study has shown that PPV with SO injection is also a safe and efficient surgical approach for treatment of primary uncomplicated RRD.⁶ The use of both gas and SO in conjunction with PPV for repair of RRD may be associated with unintentional displacement of the retina.⁷⁻¹²

Blue fundus autofluorescence (B-FAF) elegantly depicts this shift via lines of increased autofluorescence, which closely reflect the caliber and orientation of the adjacent retinal

vessels. These lines indicate the original location of the retinal vessels, which have been displaced along with the retina after retinal reattachment. These lines have been named retinal vessel printings (RVPs) by dell'Omo et al.⁹ and RPE vessel ghost by Lee et al.¹¹

The pathogenesis of RVPs remains uncertain. According to Shiragami et al.,⁷ they are the result of increased metabolic activity from portions of RPE previously shaded by the retinal vessels and then acutely exposed to light irradiation because of retinal vessel displacement. Conversely, dell'Omo et al.¹³ proposed that a different composition and characteristics of fluorophores might exist between the RPE cells belonging to RVPs (normally shaded by the overlying vessels) and the neighboring cells (normally exposed to light). The RVPs would indicate these long-standing differences, and thus, they would be not induced but simply unveiled by the displacement. Optical coherence tomography (OCT) images do not reveal peculiar abnormalities in correspondence of RVPs.⁹



Factors contributing to the retinal slippage and to its direction (generally downward, rarely upward) are not completely understood. It has been reported that the extent of RRD and face-down posturing adopted immediately after the end of surgery may respectively increase and reduce the incidence of displacement.^{7,10,11,14} It has also been proposed that the direction of displacement can vary depending on the tamponade used.¹⁰

Because the retinal displacement may cause postoperative visual disturbances like metamorphopsia and vertical diplopia, it is advisable to gain more accurate insights into the factors that promote its occurrence.

For example, the potential role of the location of the detachment and of the number and location of retinal breaks have not yet been explored in detail. Furthermore, very few cases of displacement in primary cases of RRD tamponated with SO have been reported.^{10,11} The goal of this study was to investigate prospectively the incidence and the role of factors involved in retinal displacement in eyes undergoing PPV for repair of primary, macula-off RRD and tamponated with either gas or SO.

METHODS

This prospective observational study included patients treated for primary, macula-off, uncomplicated RRD at two tertiary referral centers (University of Molise, Campobasso, Italy, and Catholic University of Sacred Heart, Rome, Italy, respectively) by two experienced surgeons between June 2012 and June 2014. Uncomplicated RRD were defined as RRD without proliferative vitreoretinopathy (PVR) or with PVR grade A (vitreous haze and pigment) or grade B (wrinkling of the inner retinal surface, retinal stiffness, rolled edge of breaks, and vessel tortuosity).¹⁵

All subjects were treated in accordance with the Declaration of Helsinki. This study was approved by the institutional Review Board of the University of Molise and Catholic University of Sacred Heart of Rome. Informed consent was obtained from all participants.

Preoperative data collection included a complete medical and ophthalmic history, logarithm of the minimum angle of resolution (logMAR) best-corrected visual acuity (BCVA) tested on the Early Treatment Diabetic Retinopathy Study (ETDRS) chart at 4 m, characteristics of detachment (location, quadrants involved, location and number of retinal breaks, and fovea status), lens status, and time from the onset of symptoms suggestive of RRD to surgery. If further breaks were noted intraoperatively, they were reported and considered in the final data analysis. We included only macula-off cases because a displacement involving the macular area may have more relevant repercussions on surgical outcomes in comparison to a displacement affecting only the peripheral retina.

Exclusion criteria included macula-on detachments, dense ocular media, preexisting macular conditions (e.g., AMD, vascular occlusive diseases, diabetes, pathologic myopia), history of previous retinal detachment, presence of PVR grade C or greater,¹⁵ presence of giant retinal tear (GRT), redetachment during follow-up, and preoperative or postoperative changes (e.g., overt macular epiretinal membranes [ERMs] and residual subretinal fluid) that were likely to interfere with accurate evaluation of images (Fig. 1).

We also excluded eyes with a spherical equivalent of refractive error more than -8.0 or $+3.0$ diopters (D). Follow-ups including repeated ophthalmologic examinations were scheduled at 1, 3, 6, and 12 months after the surgical procedure.

Imaging

Images were acquired with Spectralis HRA+OCT (Heidelberg Engineering, Heidelberg, Germany), which combines a confocal scanning laser ophthalmoscope with spectral-domain OCT. B-FAF (excitation wavelength at 488 nm and barrier filter at 500 nm), infrared, and red-free pictures (50° and 35°) were obtained the day before the operation and at each follow-up examination. The macula and fovea status and the presence of ERMs were confirmed by preoperative OCT scans.

Postoperatively, two graders (SdT, AS) independently assessed the presence of RVPs and their position (upward or downward) in relation to the adjacent retinal vessels. When there was disagreement between the two graders, a third grader (RdO) decided which grader's judgment should be accepted.

RVPs were defined as lines of increased autofluorescence running approximately parallel to adjacent retinal vessels, separated from them and closely reflecting their caliber and orientation. The presence of RVPs was taken as evidence of retinal displacement.

Surgical Procedure

Local anesthesia was induced by peribulbar block. Twenty-five-gauge PPV was performed in all cases using a Constellation vitrectomy system (Alcon Labs, Fort Worth, TX, USA). If necessary, a posterior vitreous detachment was induced via suction with the vitrectomy probe around the optic nerve head. A central and peripheral vitrectomy with scleral indentation was performed, and the vitreous base was shaved to relieve vitreous tractions on the retinal tears. Perfluorocarbon liquid (PFCL) was used if a satisfactory flattening of the retina was not achievable by means of endodrainage of the subretinal fluid with the vitrectomy probe/extrusion cannula. None of the eyes underwent peeling of ERMs or peeling of the inner limiting membrane. After careful inspection of the periphery over 360° , the fluid/air exchange was performed with particular attention to maximal drainage of the subretinal fluid through the original breaks. No posterior retinotomies were performed. Transscleral cryopexy or endolaser treatment were performed around the retinal breaks. Finally, 20% of the sulfur hexafluoride (SF₆) gas or 1000 centistokes SO (polydimethylsiloxane [PDMS]) was used as the internal tamponade. Specifically, SF₆ was used for cases without PVR or PVR grade A, whereas SO was used for cases with PVR grade B.

The patients were placed prone in the operating room immediately after completion of the procedure for at least 2 hours. Subjects were then asked to maintain the prone posture over the next 24 hours after surgery.

Orthoptic Examination

All patients underwent an orthoptic examination at 3, 6, and 12 months after surgery. A synoptophore (Clement and Clark, Edinburgh, UK) was used to measure the objective angles of deviation.

Statistical Methods

Comparisons between the group with and without retinal dislocation were done using the *t*-test for continuous and the χ^2 test for categorical variables. The linear relationship between independent variables and the logit transformation of the dependent variable (retinal displacement) was tested using the Hosmer-Lemeshow test, which was also used to test

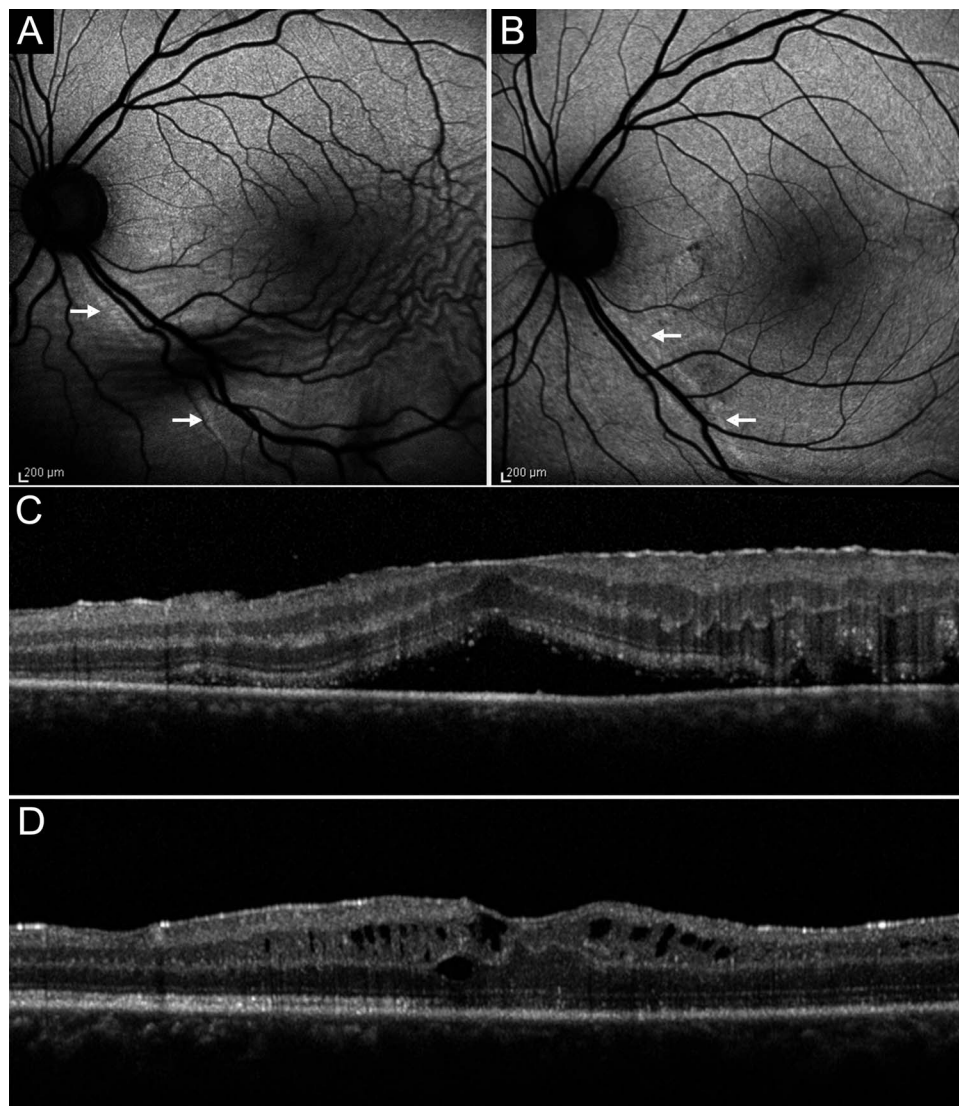


FIGURE 1. Influence of a gross ERM on the location of the RVPs evaluated by B-FAF (A, B) and OCT (C, D) pre- and postoperatively. (A) Preoperatively, B-FAF image shows an inferior detachment involving the macula and RVPs (arrows) located inferiorly to the infero-temporal arcades, indicating an upward displacement of the retina. (B) Three months after successful repair of RRD and peeling of the ERM, the retina looks attached on B-FAF image, and RVPs (arrows) are now located superiorly to the corresponding retinal vessels, indicating a downward displacement of the retina. (C) Preoperatively, an ERM altering the foveal contour is visible on a horizontal OCT scan passing through the fovea. (D) Three months after repair of RRD and peeling of the ERM, the horizontal OCT scan, taken at the same location, shows an attached macula with a partially restored foveal pit.

the goodness of fit. To avoid overfitting, only the following predictor variables were included in the multiple logistic regression model: duration of detachment, lens status at baseline, detachment localization, quadrants involved, fovea status, breaks location, breaks number, PFCL use, and type of tamponade.

The hypothesis that the localization of detachment and the localization of breaks could influence the postoperative direction of displacement was also tested. To this aim, the direction of dislocation and the detachment location were treated as continuous variables ($-1 =$ inferior, $0 =$ balanced, $1 =$ superior displacement/break or detachment) to calculate a one-tailed Spearman's ρ .

The relationship between retinal displacement and modifications of visual acuity after operation was studied using Student's *t*-test and retinal displacement as factor. The angles of deviation recorded at each planned orthoptic examination were compared using Friedman's test.

The statistical analysis was carried out using SPSS 13.0 statistical software (SPSS, Inc., Chicago, IL, USA). $P < 0.05$ was considered significant.

RESULTS

Between June 2012 and June 2014, 152 eyes that were eligible to be enrolled into the study according to the inclusion and exclusion criteria underwent PPV for RRD at two Institutional centers. Thirty-five enrolled patients were subsequently excluded because of redetachment during follow-up ($n = 14$), presence of overt ERM ($n = 8$), media opacities preventing adequate postoperative imaging ($n = 9$), and inability to attend the follow-up visits ($n = 4$).

The remaining 125 subjects (99 males, 26 females) were followed for 12 months. The mean age was 60.9 ± 11.7 years (range, 24–81 years). At enrollment, 46 (36.8%) eyes were

phakic and 79 (63.2%) pseudophakic. During follow-up, 16 patients underwent cataract extraction. The median duration (95% confidence interval [CI]) of retinal detachment based on the self-reported symptoms was 7 (range, 5–7) days. Detachment was located in the superior hemisphere of the retina in 31 (24.8%) eyes, inferior hemisphere in 12 (9.6%) eyes, and involved both superior and inferior hemispheres in 82 (65.6%) eyes. Sixty-seven (53.6%) eyes had RRD involving two quadrants, 26 (20.8%) involving three quadrants, and 32 (25.6%) involving four quadrants. All cases were macula-off, but on the basis of the preoperative OCT examination, the fovea was attached in 23 of 125 cases (18.4%). Breaks were located in the upper quadrants in 81 (64.8%) eyes, in the lower quadrants in 16 eyes (12.8%), and in both upper and lower quadrants in 28 (22.4%) eyes.

PFCL was used in 80 (64%) eyes. Ninety-seven (77.6%) eyes were tamponated with gas, and 28 (22.4%) eyes received 1000 centistokes PDMS that was removed (mean \pm SD) 2.8 ± 0.9 months after the first operation.

After retinal reattachment, retinal displacement was observed in 44 of 125 eyes (35.2%) based on the presence of RVPs on B-FAF imaging on the occasion of the first follow-up appointment scheduled at 1 month after operation. There was 100% agreement between the two graders relative to the presence and location of RVPs in relation to the corresponding retinal vessels. As observed in a previous study,⁹ OCT sections of RVPs did not reveal characteristic features (data not shown).

Over the course of follow-up, caliber, orientation, and distance of RVPs from the adjacent retinal vessels remained generally stable. In the eyes tamponated with SO, presence and location of the RVPs in relation to the adjacent retinal vessels did not change after removal of SO ($P = 0.5$).

The group with and without retina displacement were comparable for age, sex, preoperative BCVA, and duration of detachment, as well as for anatomic variables such as lens status, location and extent of RRD, fovea status, and number and location of breaks (Table 1). Intraoperative use of PFCL did not significantly differ between the two groups.

The extent of retinal detachment (number of quadrants involved) did not affect the rate of displacement, which was 35.8%, 34.6%, and 35.5% in eyes with two, three, and four quadrants of RRD, respectively ($P = 0.8$).

The type of tamponade—specifically the use of gas—was the only variable that was significantly associated with retinal displacement ($P = 0.009$). In fact, 40 of 97 (41.2%) eyes tamponated with gas versus only 4 of 28 (14.3%) eyes tamponated with SO showed retinal displacement.

The group tamponated with gas and the group tamponated with SO were comparable for age, sex, preoperative BCVA, and duration of detachment. Nevertheless, there were more cases in which breaks and detachment involved both the upper and lower quadrants in the SO group versus the gas group (43% vs. 17%, $P = 0.003$ and 85% vs. 61%, $P = 0.01$, respectively). These two groups also differed in the number of detached quadrants (two quadrants: 25% vs. 62%; three quadrants: 32% vs. 17%; four quadrants: 43% vs. 21% in the SO and gas groups, respectively; $P = 0.0009$).

To better analyze the relationship between retinal displacement and type of tamponade, we used a multiple logistic regression model with retinal displacement as outcome and several variables as predictors. The type of tamponade was the only significantly predictor of retinal displacement (odds ratio, 5.3; $P = 0.007$; Table 2).

The logarithm of the minimum angle of resolution BCVA significantly improved from 1.3 ± 0.8 to 0.4 ± 0.3 ($P < 0.0001$) at 12-month follow-up (from 1.3 ± 0.8 to 0.4 ± 0.3 and from 1.4 ± 0.7 to 0.3 ± 0.2 for the groups without and with displacement, respectively; $P = 0.15$; Table 1).

TABLE 1. Main Pre-, Intra-, and Postoperative Characteristics of the Groups Without and With Retinal Displacement After Repair of Macula-Off RRD

	Retinal Displacement Absent	Retinal Displacement Present	<i>P</i>
Number of patients (eyes)	81	44	
Sex (M/F)	55/26	34/10	0.19*
Age (mean \pm SD)	61 \pm 1.4	60 \pm 1.7	0.71†
Eye (OD/OS)	47/34	25/19	0.52*
Lens status at baseline, <i>n</i> eyes (%)			0.26*
Phakic	32 (39.5)	14 (31.8)	
IOL	49 (60.5)	30 (68.2)	
Detachment duration (days, mean \pm SD)	8.9 \pm 1.0	9.2 \pm 1.0	0.82†
Detachment location, <i>n</i> eyes (%)			0.67*
Sup	22 (27.2)	9 (20.4)	
Sup+Inf	52 (64.2)	30 (68.2)	
Inf	7 (8.6)	5 (11.4)	
Quadrants of RRD, <i>n</i> eyes (%)			0.99*
2	43 (53.1)	24 (54.5)	
3	17 (21)	9 (20.5)	
4	21 (25.9)	11 (25)	
Preoperative fovea status on OCT, <i>n</i> eyes (%)			0.4*
On	16 (19.9)	7 (15.9)	
Off	65 (80.2)	37 (84.1)	
Breaks location, <i>n</i> eyes (%)			0.84*
Sup	51 (63)	30 (68.2)	
Sup+Inf	19 (23.4)	9 (20.4)	
Inf	11 (13.6)	5 (11.4)	
Breaks number/eyes (mean \pm SD)	2.2 \pm 0.2	2.1 \pm 0.2	0.62†
PFCL use, <i>n</i> eyes (%)			0.47*
Yes	50 (61.7)	30 (68.2)	
No	31 (38.3)	14 (31.8)	
Tamponade			0.009*
Gas	57 (70.4)	40 (90.9)	
Silicone oil	24 (29.6)	4 (9.1)	
BCVA at baseline	1.3 \pm 0.8	1.4 \pm 0.7	0.45†
BCVA at 12-month follow-up	0.4 \pm 0.3	0.3 \pm 0.2	0.15†

P values in bold are statistically significant. F, female; Inf, inferior; IOL, intraocular lens; M, male; OD, oculus dexter; OS, oculus sinister; Sup, superior.

* χ^2 *P* value.

† *t*-test *P* value.

Thus, the displacement of the retina did not affect the logMAR BCVA outcome at 12 months after operation.

Direction of Displacement

Overall, the displacement was downward in 39 (88.6%) cases and upward in 5 (11.4%) cases. Thus, downward displacement was by far more common than upward displacement (Figs. 2, 3). This was independent of the location of the detachment (superior, inferior, or superior + inferior). The highest incidence of downward displacement was observed for inferior detachments (41.7%) and the lowest incidence for

TABLE 2. Logistic Regression Analysis Model of Studied Variables Associated With Displacement of Retina

Variable	OR (95% CI)	P	B (SE)
Lens status at baseline (phakic/IOL)	0.6 (0.3-1.5)	0.3*	-0.4 (0.43)
Detachment duration (days)	1.0 (0.9-1.1)	0.7†	0.01 (0.09)
Detachments localization (Sup/Sup+Inf/Inf)	1.3 (0.8-2.2)	0.34*	0.26 (0.27)
Quadrants involved (2/3/4, n eyes)	0.9 (0.5-1.6)	0.77*	-0.08 (0.3)
Preoperative fovea status on OCT (on/off)	0.7 (0.2-2.1)	0.5*	-0.38 (0.6)
Breaks location (Sup/Sup+Inf/Inf)	1.1 (0.6-1.9)	0.86*	0.05 (0.3)
Breaks number	0.95 (0.7-1.3)	0.74†	-0.05 (0.15)
PFCL use (yes/no)	0.7 (0.3-1.7)	0.62*	-0.32 (0.44)
Tamponade (gas, silicone oil)	5.3 (1.6-18.0)	0.007*	1.67 (0.62)

P values in bold are statistically significant. Goodness of fit was calculated using the Hosmer-Lemeshow test ($P = 0.51$). Inf, inferior; Sup, superior.

* χ^2 P value.

† t-test P value.

superior detachments (22.6%). Detachments involving both the superior and inferior hemispheres had an incidence of downward displacement of 35.7%.

Upward dislocation occurred only in cases of superior or superior + inferior detachments (Fig. 4). No cases of upward dislocation were observed in association with detachments confined to the inferior quadrants (Fig. 5).

No correlation was found between the direction of retinal displacement versus the localization of retinal detachments ($P = 0.09$) or versus the localization of retinal breaks ($P = 0.29$).

The use of gas was associated with downward and upward displacement in 36 (90%) and 4 (10%) cases, respectively, whereas the SO was associated with downward and upward dislocation in 3 (75%), and 1 (25%) cases, respectively.

Objective measurements taken using the synoptophore, 3 months after operation, in the 44 eyes with retinal displacement, showed extorsion between 1° and 5° in 28 eyes, intorsion between 1° and 3° in 3 eyes, and vertical deviation between 1° and 4° in 13 eyes. Measurements taken at 6- and 12-month follow-up appointments did not show significant changes ($P = 0.8$).

Orthoptic examination of the 81 patients without retinal slippage showed absence of a manifest strabismic deviation. None of the 125 patients complained of cyclovertical diplopia or slant at any time during the postoperative follow-up.

DISCUSSION

This prospective study shows that unintentional displacement of the retina after repair of primary, uncomplicated macula-off detachments with PPV occurs in more than one third of cases despite prone posturing taken immediately after operation. The displacement is observed more frequently in association with gas than SO. Downward and upward displacements may be observed with either tamponade, but downward dislocation is much more common. Among the studied factors, potentially implicated in favoring displacement, only the use of gas was found to be significant.

Over the last years, PPV has become the method of choice for treating primary RRDs. Although a recent meta-analysis¹⁶ of prospective, randomized, and controlled trials studying PPV versus scleral buckling concluded that there were no significant differences in the results of primary reattachment rate between the two groups, currently, many retinal specialists would choose PPV as the primary approach for the management of uncomplicated RRD. This is because growing advances in instrumentation technology, including direct visualization of vitreous tractions on the retina during surgical maneuvers and the possibility of witnessing the retina reattach intraoperatively, have made this technique more and more popular.¹⁻⁵ When PPV is performed, a tamponade is usually left in the eye at the end of surgery. The use of a tamponade, either gas or SO, may be associated with unintentional displacement of the retina.

In 2010, Shiragami et al.⁷ first reported unintentional retinal displacement in a series of 43 patients operated on with PPV and gas for bullous and superior RRDs. The unintentional displacement occurred in 62.8% of the operated eyes. This was significantly associated with the RRD extent and was directed downward in all cases. The authors hypothesized that in eyes filled with gas, the sitting position taken immediately after operation may promote a downward shift of residual subretinal fluid due to the force of gravity and thus cause the displacement. The same authors subsequently reported that earlier implementation of prone positioning substantially reduced the chance of retinal slippage.¹⁴ Other studies¹⁰⁻¹² in which prone posturing was generally recommended but with variable modalities reported variable incidences of displacement ranging from 60% to 72%.

In this current study, all patients were asked to keep a strict prone posture in the operating theatre for at least 2 hours after operation and during the following 24 hours regardless of choice of tamponade. Furthermore, to better compare the influence of gas versus SO on displacement, direct exchange PFCL/SO was not allowed, so all eyes underwent a fluid/air exchange before receiving the final tamponade. Cases with potential confounders like PVR grade C or worse¹⁵ and GRTs that are known risk factors for retinal slippage^{17,18} were deliberately excluded. Similarly, cases with overt ERMs were excluded because the presence of RVPs in eyes with prominent ERMs and a history of RRD could be either caused by a genuine full-thickness displacement of the retina (secondary to RRD) or to a shift involving only the superficial retinal layers (secondary to the traction exerted by the ERM on the inner retina).^{13,19}

After excluding these confounders, we still found that the incidence of displacement greatly differed in the group tamponated with gas versus the group tamponated with SO (41.2% vs. 14.3%).

If the hypothesis formulated by Shiragami et al.⁷ is correct, it is possible that the injection of SO in an eye filled with air, squeezing the residual subretinal fluid (accumulated at the posterior pole by the air-fluid exchange) toward the breaks located in the anterior retina and favoring its egression, may reduce the chances of retina slippage.

However, we believe that the different rate of displacement observed in association with gas and SO is rather due to the different physical properties of the two tamponades.

The shape and the relationship with the retina surface of bubbles of tamponades are influenced by three main properties: specific gravity, surface tensions, and buoyancy force. In comparison to gases, including air, 1000 centistokes SO has a much higher specific gravity (0.001 vs. 0.97 g/mL), a lower interfacial tension (70 vs. 35 mN/m),²⁰ and a much lower buoyancy force. Consequently, it has been estimated that the

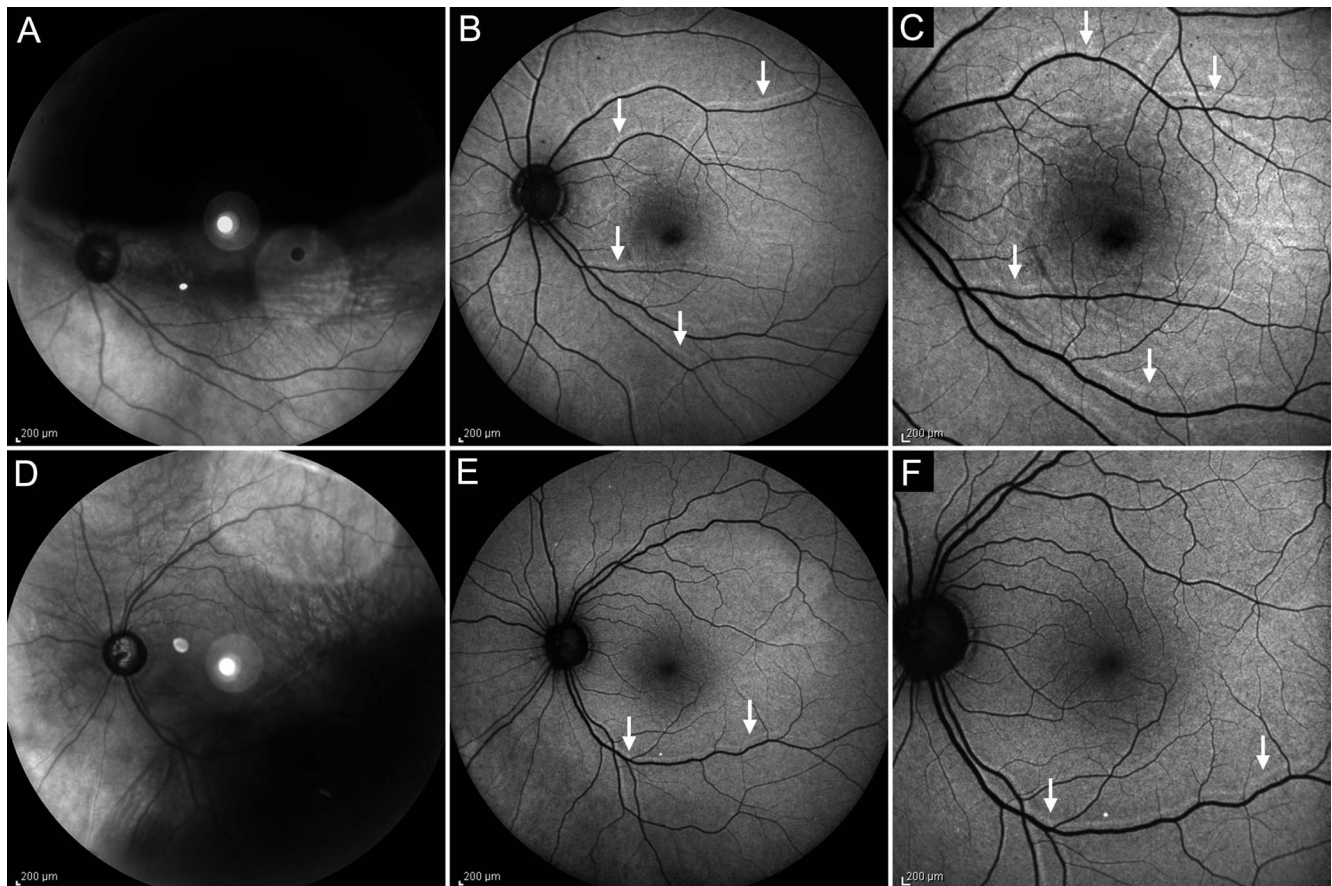


FIGURE 2. Downward displacement of the retina observed on B-FAF images after repair of RRD with vitrectomy and gas. (A) The 50° infrared image shows a superior, bullous, macula-off detachment. Three months after successful repair of RRD, 50° (B) and 35° (C) B-FAF images show RVPs (arrows) superiorly to the corresponding retinal vessels, indicating a downward displacement of the retina. (D) The 50° infrared image shows an inferior, macula-off detachment. Three months after successful repair of RRD, 50° (E) and 35° (F) B-FAF images show RVPs (arrows) superiorly to the corresponding retinal vessels, indicating a downward displacement of the retina.

force exerted on the retina by a SO bubble is ~30 times lower than that of a bubble gas of equal volume.²¹

Thus, for a certain volume, gas bubbles have a higher contact angle and a greater surface area in contact with the retina (the gas bubble has a flat-bottomed shape) than SO that

forms a more spherical bubble and has a relatively lower surface area in contact with the retina. This means that a slightly smaller than ideal bubble of SO might leave many clock hours of retina uncovered. In fact, in an experimental eye model, an 80% fill with SO would guarantee only a 180°

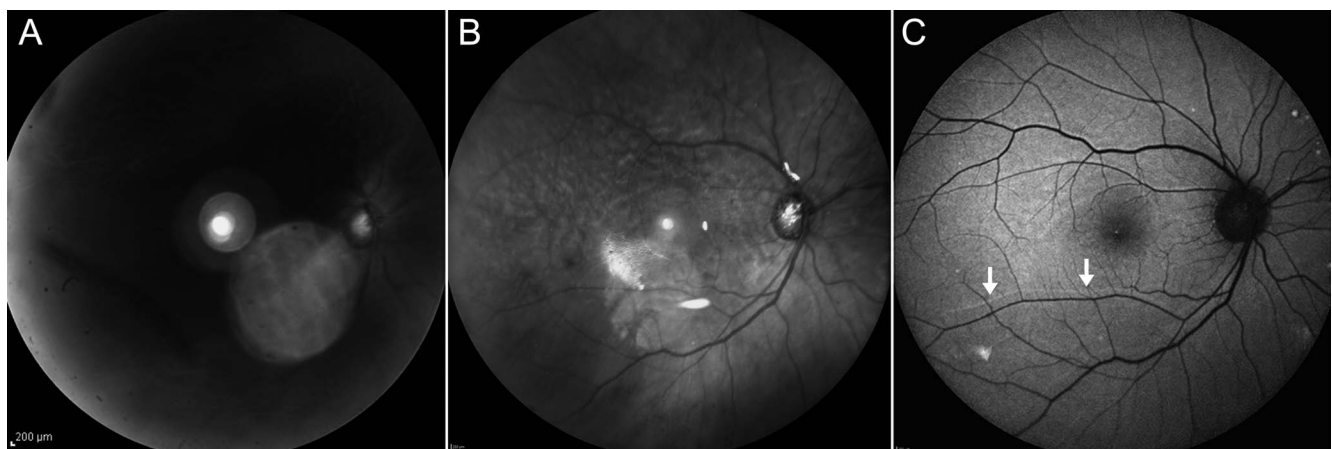


FIGURE 3. Downward displacement of the retina observed on B-FAF images after repair of RRD with vitrectomy and 1000 centistokes silicone oil. (A) Preoperatively, the 50° infrared image shows a total retinal detachment. One month after successful repair of RRD, the retina looks attached on IR image (B), and the B-FAF image (C) shows RVPs (arrows) superiorly to the corresponding retinal vessels, indicating a downward displacement of the retina.

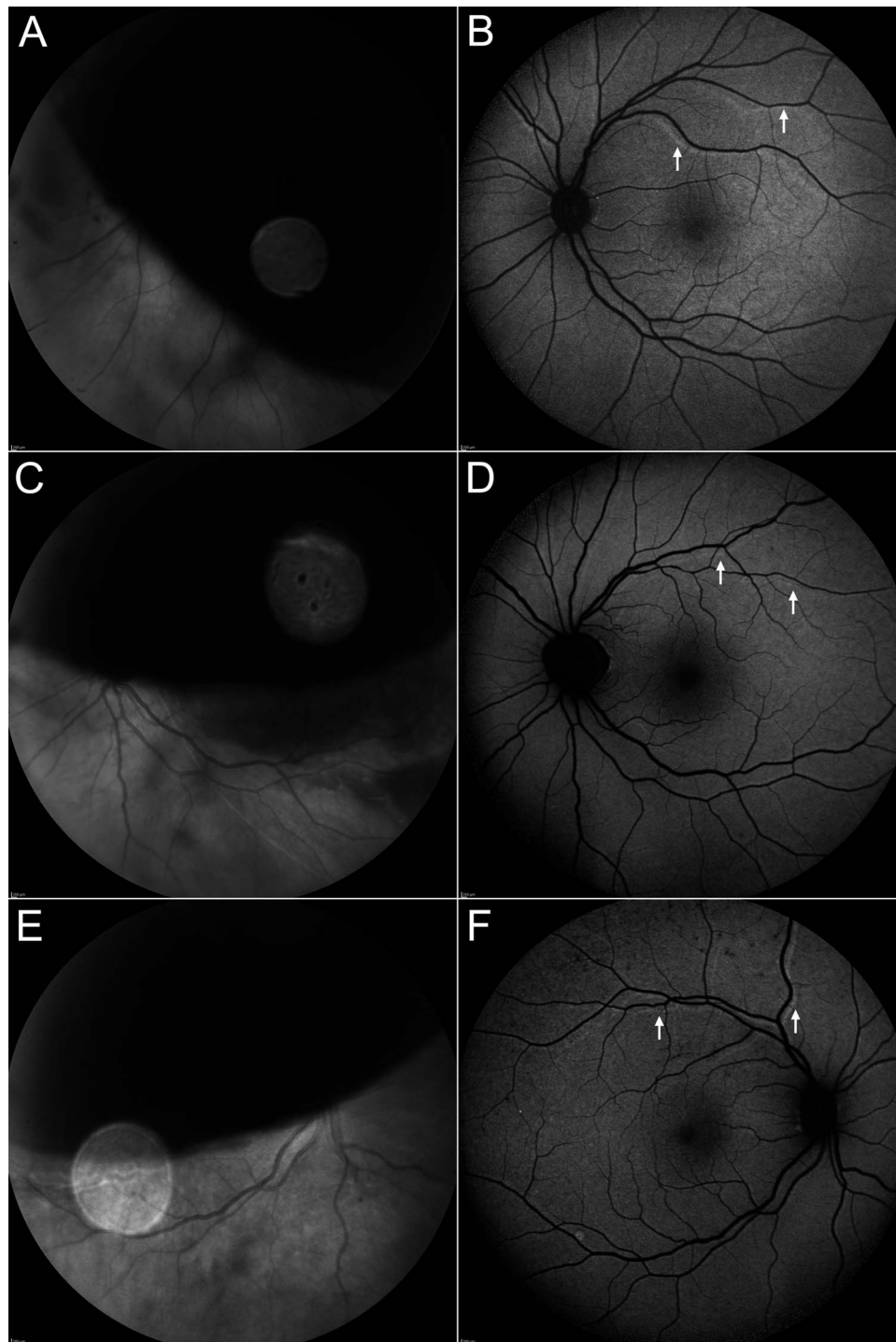


FIGURE 4. Upward displacement of the retina observed on B-FAF images after repair of bullous, macula-off RRDs with vitrectomy and gas. Preoperative infrared images (A, C, E) and B-FAF images (B, D, F) taken 3 months after successful repair of RRDs that show RVPs running inferiorly to the corresponding retinal vessels, indicating an upward displacement of the retina.

angle of tamponade.²² Consequently, the SO bubble, leaving a portion of the detached retina uncovered, may favor a more gradual and slow reabsorption of the subretinal fluid in comparison to gas, especially if the filling is not perfect. This would give the detached and stretched retinal surface time to decrease and to smoothly match its original location. Conversely, in the presence of gas, the retinal tissue is acutely pushed toward the RPE, and this increases the chances that the detached retina with increased surface

(because stretched by the underlying fluid) does not match the original location.

In accordance with Cobos et al.¹² and in contrast to other authors,^{7,10,11} we found no association between RRD extent and displacement incidence in the gas group (a similar analysis for the SO group was not possible because of the few cases). This discrepancy could be due to the characteristics of our sample that differs from previous series because it included many cases with three or four quadrants of RRD (20.8% and

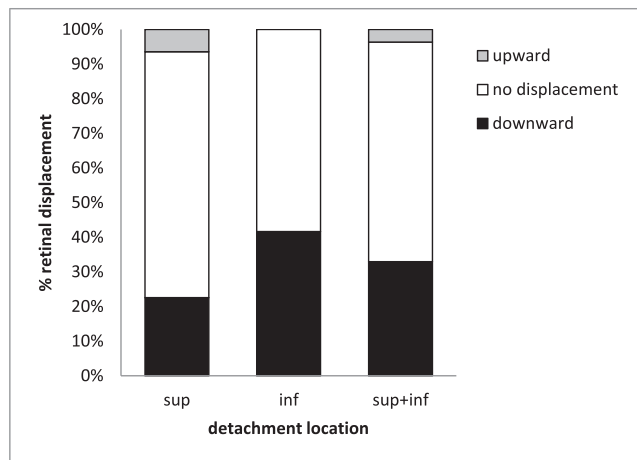


FIGURE 5. Relationship between location of RRD and incidence of retinal displacement after repair of RRD with vitrectomy and tamponade (sulfur hexafluoride gas or 1000 centistokes silicone oil).

25.6%, respectively) and no cases with only one quadrant of RRD.

A novel and interesting finding of this study, not reported before, is that upward displacement of the retina may occur also in cases tamponated with gas. However, in line with previous reports, we found that downward displacement occurs much more commonly than upward displacement in eyes receiving gas. Another interesting finding emerging from the current study is that downward displacement is more common also in cases tamponated with silicone oil. The reason why the retina tends to rarely move upward and preferentially moves downwards despite the immediate adoption of a prone posture and independent of type of tamponade used remains poorly understood. One possible explanation is that, because of the force of gravity and because both gas and SO are lighter than water, the residual subretinal fluid tends to move downward along with the retina rather than upward. Supporting this hypothesis is the fact that neither location of detachment nor location of breaks seemed to be relevant in influencing the direction of dislocation in this series. However, studies recruiting larger cohorts are warranted to clarify this aspect.

Prior to this report, only 11 cases of RRD tamponated with SO have been studied for the presence of RVPs, with displacement occurring only in four (three upward and one downward).^{10,11} Noteworthy, some of these cases showed characteristics that, in our opinion, might have substantially contributed to the occurrence of displacement. In fact, two of these four cases presented with GRT: one was further complicated by PVR, the grade of which was not specified. As discussed above, both the presence of GRTs and ERMs in the context of PVR may influence both the occurrence and the direction of displacement. For these reasons, we decided to exclude cases with GRTs and prominent ERMs from this prospective series, and, as expected, we found an incidence of retinal slippage in eyes tamponated with SO lower than that reported before.¹⁰

In accordance with previous observations, we found that the use of PFCL does not have a substantial role in reducing the incidence of displacement.^{7,10,14} This could be secondary to the fact that a complete drainage of subretinal fluid is not achievable despite PFCL use as shown by intraoperative OCT studies.^{23,24} Alternatively, this might suggest that small amounts of residual subretinal fluid at the end of operation do not play a crucial role in causing/avoiding the displacement.

This is also supported by the fact that adjuvant posterior retinotomies did not show to reduce the rate of unintentional slippage.^{8,10}

The BCVA at 12 months after operation did not differ in the group with and without displacement. Other authors found similar results.¹² Thus, although unintentional retinal slippage may cause visual disturbances such as binocular diplopia⁷ and metamorphopsia, it does not seem to affect the visual outcome. In the present series, in line with previous reports,^{7,14} none of the 44 patients with displacement had binocular diplopia.

We acknowledge several limitations to our study. First, the sample analyzed is relatively small, although it is the largest one reported thus far for cases tamponated with SO.

Second, there was no randomization for the cases treated with either gas or SO because the choice of tamponade was made on the basis of the grade of PVR. However, we do not believe that early stages of PVR (i.e., PVR grade A or B) may play a significant role in favoring/avoiding displacement compared with cases without PVR. Furthermore, a proper randomization that implied the use of SO in cases without any grade of PVR would hardly be feasible.

Third, the group tamponated with gas and the group tamponated with SO differed with respect to some baseline features like number of detached quadrants and concomitant involvement of the upper and lower quadrants (both more common in the SO group). However, on the basis of these preoperative characteristics and on the basis of what has been reported in the literature, we would have expected to find a higher rate of displacement in the SO group. Conversely, we found a rate of displacement much lower in the SO than in the gas group.

Fourth, metamorphopsia was not systematically measured in the patients enrolled in this study and the correlation between presence of displacement and metamorphopsia was not investigated. However, this study was not designed to explore the relationship between displacement and metamorphopsia. Furthermore, it should be bore in mind that macula-off detachments may bring about multiple retinal changes (i.e., irregularities of the outer retinal bands, reduced retinal thickness, outer retinal folds, unintentional retinal displacement, intra- or subretinal fluid), which may all cause postoperative metamorphopsia. Segregating the contribution of each of these retinal changes in causing metamorphopsia is extremely difficult and probably not feasible.

The strengths of this study include its prospective design and the fact that SO was used in a relatively large number of cases that were not complicated by overt ERM, GRTs, or PVR grade C or worse, conditions that are likely to increase the chances of displacement and interfere with a correct interpretation of the results. Furthermore, we showed that upward displacement of the retina may, although rarely, be observed also in eyes tamponated with gas.

In conclusion, this study shows that unintentional displacement of the retina after repair of primary and uncomplicated macula-off detachments with PPV may be observed using either gas or SO and despite prone posturing taken immediately after operation and kept for 24 hours. Downward and upward displacements may occur with either tamponade, but the reason why downward dislocation is much more common is poorly understood. Among the factors potentially implicated in favoring the displacement that were studied, only the use of gas was found to be significant.

Acknowledgments

Disclosure: **R. dell’Omo**, None; **A. Scupola**, None; **D. Viggiano**, None; **M.G. Sammarco**, None; **S. De Turrís**, None; **M.R.**

Romano, None; G. Grimaldi, None; E. dell'Omo, None; C. Costagliola, None

References

1. Heimann H, Bartz-Schmidt KU, Bornfeld N, et al. Scleral buckling versus primary vitrectomy in rhegmatogenous retinal detachment: a prospective randomized multicenter clinical study. *Ophthalmology*. 2007;114:2142-2154.
2. Sodhi A, Leung LS, Do DV, Gower EW, Schein OD, Handa JT. Recent trends in the management of rhegmatogenous retinal detachment. *Surv Ophthalmol*. 2008;53:50-67.
3. De la Rúa ER, Pastor JC, Fernández I, et al. Non-complicated retinal detachment management: variations in 4 years. Retina 1 project; report 1. *Br J Ophthalmol*. 2008;92:523-525.
4. Ho JD, Liou SW, Tsai CY, Tsai RJ, Lin HC. Trends and outcomes of treatment for primary rhegmatogenous retinal detachment: a 9-year nationwide population-based study. *Eye (Lond)*. 2009;23:669-675.
5. Falkner-Radler CI, Myung JS, Moussa S, et al. Trends in primary retinal detachment surgery: results of a Bicenter study. *Retina*. 2011;31:928-936.
6. Antoun J, Azar G, Jabbour E, et al. Vitreoretinal surgery with silicone oil tamponade in primary uncomplicated rhegmatogenous retinal detachment: clinical outcomes and complications. *Retina*. 2016;36:1906-1912.
7. Shiragami C, Shiraga F, Yamaji H, et al. Unintentional displacement of the retina after standard vitrectomy for rhegmatogenous retinal detachment. *Ophthalmology*. 2010;117:86-92.
8. Pandya VB, Ho IV, Hunyor AP. Does unintentional macular translocation after retinal detachment repair influence visual outcome? *Clin Exp Ophthalmol*. 2012;40:88-92.
9. dell'Omo R, Mura M, Lesnik Oberstein SY, Bijl H, Tan HS. Early simultaneous fundus autofluorescence and optical coherence tomography features after pars plana vitrectomy for primary rhegmatogenous retinal detachment. *Retina*. 2012;32:719-728.
10. Codenotti M, Fogliato G, Iuliano L, et al. Influence of intraocular tamponade on unintentional retinal displacement after vitrectomy for rhegmatogenous retinal detachment. *Retina*. 2013;33:349-355.
11. Lee E, Williamson TH, Hysi P, et al. Macular displacement following rhegmatogenous retinal detachment repair. *Br J Ophthalmol*. 2013;97:1297-1302.
12. Cobos E, Rubio MJ, Arias L, et al. Incidence and relation with anatomical and functional variables of postoperative macular displacement in rhegmatogenous retinal detachment. *Retina*. 2016;36:957-961.
13. dell'Omo R, Cifariello F, dell'Omo E, et al. Influence of retinal vessel printings on metamorphopsia and retinal architectural abnormalities in eyes with idiopathic macular epiretinal membrane. *Invest Ophthalmol Vis Sci*. 2013;54:7803-7811.
14. Shiragami C, Fukuda K, Yamaji H, Morita M, Shiraga F. A method to decrease the frequency of unintentional slippage after vitrectomy for rhegmatogenous retinal detachment. *Retina*. 2015;35:758-763.
15. Machemer R, Aaberg TM, Freeman HM, Irvine AR, Lean JS, Michels RM. An updated classification of retinal detachment with proliferative vitreoretinopathy. *Am J Ophthalmol*. 1991;112:159-165.
16. Soni C, Hainsworth DP, Almony A. Surgical management of rhegmatogenous retinal detachment: a meta-analysis of randomized controlled trials. *Ophthalmology*. 2013;120:1440-1447.
17. Shunmugam M, Ang GS, Lois N. Giant retinal tears. *Surv Ophthalmol*. 2014;59:192-216.
18. Hoffman ME, Sorr EM. Management of giant retinal tears without scleral buckling. *Retina*. 1986;6:197-204.
19. Nitta E, Shiraga F, Shiragami C, Fukuda K, Yamashita A, Fujiwara A. Displacement of the retina and its recovery after vitrectomy in idiopathic epiretinal membrane. *Am J Ophthalmol*. 2013;155:1014-1020.
20. Krzystolik MG, D'Amico DJ. Complications of intraocular tamponade: silicone oil versus intraocular gas. *Int Ophthalmol Clin*. 2000;40:187-200.
21. Petersen J. The physical and surgical aspects of silicone oil in the vitreous cavity. *Graefes Arch Clin Exp Ophthalmol*. 1987;225:452-456.
22. Fawcett I, Williams RL, Wong D. Contact angles of substances used for internal tamponade in retinal detachment surgery. *Graefes Arch Clin Exp Ophthalmol*. 1994;32:438-444.
23. Ehlers JP, Ohr MP, Kaiser PK, Srivastava SK. Novel micro-architectural dynamics in rhegmatogenous retinal detachments identified with intraoperative optical coherence tomography. *Retina*. 2013;33:1428-1434.
24. Ehlers JP, Dupps WJ, Kaiser PK, et al. The Prospective Intraoperative and Perioperative Ophthalmic ImagiNg with Optical CoherEncE TomogRaphy (PIONEER) Study: 2-year results. *Am J Ophthalmol*. 2014;158:999-1007.