

Letter to the Editor (Case report)

doi:10.1093/rheumatology/keaa691

A case of psoriatic arthritis triggered by SARS-CoV-2 infection**Rheumatology key message**

- SARS-CoV-2 can trigger chronic arthritis, such as rheumatoid arthritis or spondyloarthritis, or induce reactive arthritis.

DEAR EDITOR, Several autoimmune/autoinflammatory phenomena have been described during the new coronavirus SARS-CoV-2 pandemic, including cytokine storm/macrophage-activation syndrome (MAS), vasculopathy (Kawasaki-like disease, chill-blain lesions), haematological alterations (hemolytic anaemia, anti-phospholipids), skin manifestations (urticaria, purpura), demyelinating syndromes (Guillain-Barré syndrome) and arthritis.

To date, a few cases of arthritis have been reported with SARS-CoV-2 infection. Their features partially resemble the three subgroups of arthritis possibly associated to viral infections: viral arthritis, reactive arthritis or chronic arthritis triggered by viral infection. Yokogawa and colleagues described a case of knee arthritis occurring during SARS-CoV-2 disease (COVID-19), resolving spontaneously, and then suspected for viral arthritis [1]. Four cases resembling reactive arthritis have been reported after COVID-19 resolution: polyarthritis involving lower limbs and developing 8 days after COVID-19 symptoms [2], elbow arthritis with skin psoriasis developing 10 days after COVID-19 symptoms [3], knee arthritis with balanitis [4], and bilateral ankle arthritis with mild enthesitis on day 21 after COVID-19 [5]. A few days before COVID-19 symptoms, two other patients developed polyarthritis with a chronic course and in one case with positive anti-citrullinated peptide antibodies, thus suggesting rheumatoid arthritis triggered by the virus [6, 7].

We report, herein, the case of a 27-year-old woman who developed spondyloarthritis concomitantly with SARS-CoV-2 infection. She had a personal history for irritable bowel disease and a family history for psoriasis but never showed skin/nail lesions or articular/axial involvement. At the end of February 2020, she developed acute arthritis of the left ankle followed 7 days later by anosmia and dysgeusia, without fever or cough. No specific assays were performed to detect SARS-CoV-2 and symptoms resolved spontaneously within 2 weeks. In May she developed left knee arthritis (Fig. 1A) and a skin lesion on lumbar region resembling psoriasis (Fig. 1A). Inflammatory markers were slightly increased, while rheumatoid factor, anti-citrullinated peptides, and

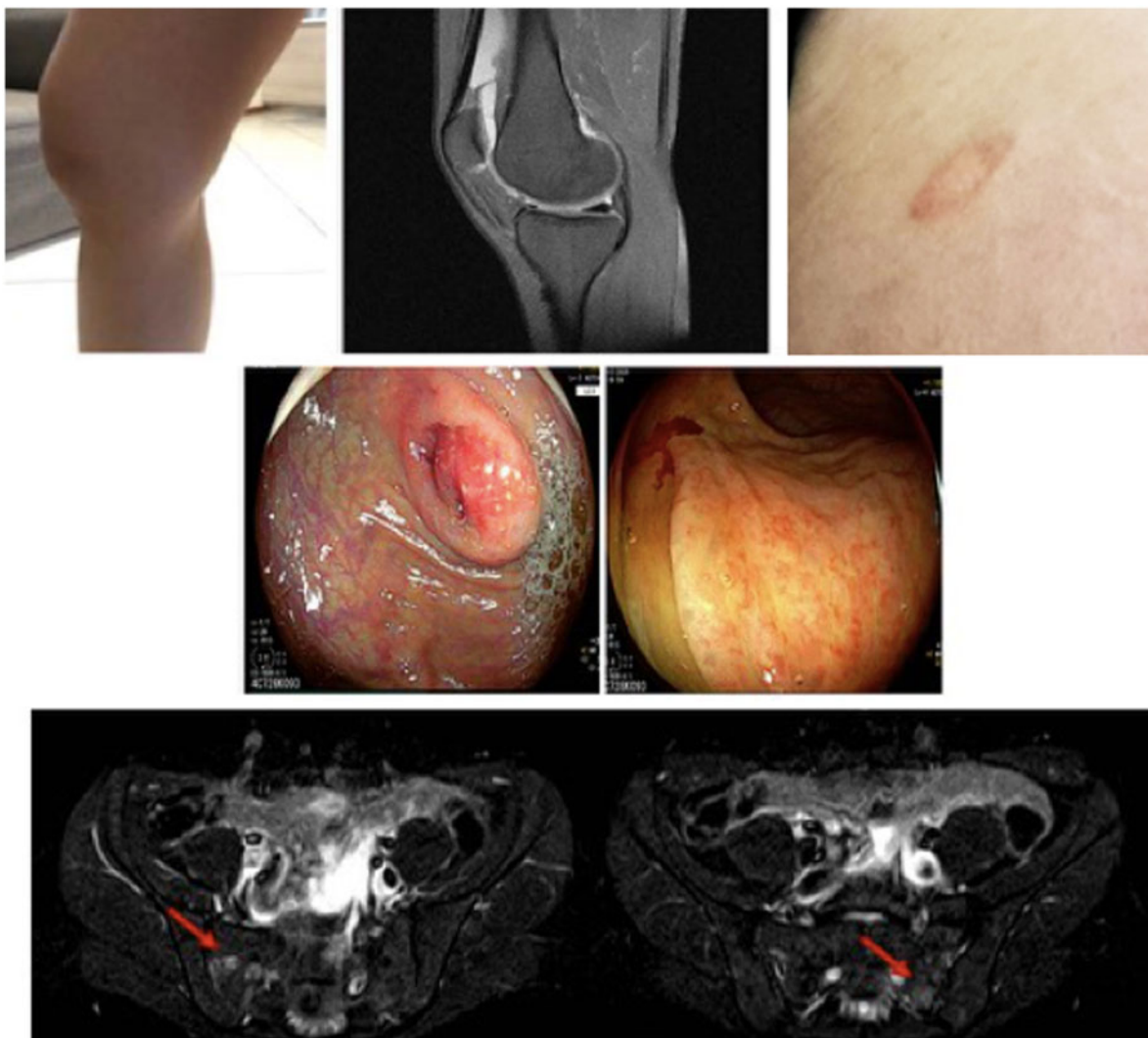
anti-nucleus antibodies were negative. MRI was performed (Fig. 1A) and an arthrocentesis followed by intra-articular steroid injection of the left knee was assessed with evacuation of 80 ml of inflammatory synovial fluid.

In July, the patient was admitted to Humanitas Research Hospital for diarrhoea, low back pain, and arthritis involving the left knee and the metatarsophalangeal joints. Colonoscopy showed erythematous lesions of the caecum and rectum, but histological examination was not specific for inflammatory bowel disease (Fig. 1B). Sacroiliac MRI showed mild bilateral sacroiliitis (Fig. 1C) and HLA-B27 was negative. She had no fever or respiratory symptoms, a nasopharyngeal swab proved negative for SARS-CoV-2, a chest CT scan was negative for COVID-19 pneumonia, anti-SARS-CoV-2 IgG were positive (28 U/ml; Elecsys, Roche Diagnostics International, Basel, Switzerland). Synovial fluid, previously collected and stored at -20°C , was negative for SARS-CoV-2 genome (Cobas 680/8800 SARS-CoV-2, Roche) and positive for anti-SARS-CoV-2 IgG (29 U/ml; Elecsys, Roche).

Therefore, psoriatic spondyloarthritis triggered by SARS-CoV-2 infection in a genetically predisposed subject was diagnosed and this is the first case reported, to our knowledge. The clinical presentation and course excluded the diagnosis of viral arthritis, which generally manifests as an acute monophasic arthritis and has a self-limiting course. Moreover, virus genome was absent in the synovial fluid, while the presence of anti-SARS-CoV-2 in the synovial fluid could be the result of blood immunoglobulins crossing the inflamed synovia, as immunoglobulin levels were very similar in the blood and synovial fluid, regardless of different sample collection time. A diagnosis of reactive arthritis was also appraised less likely considering the onset of arthritis before the clinical manifestations of viral infection, while reactive arthritis generally develops after 1–24 weeks from the infection.

The mechanisms by which SARS-CoV-2 can trigger autoimmunity and autoinflammation remain unknown. A virus-induced hyper-inflammatory milieu has been evoked in the case of MAS, while a Th17-shift has been hypothesized in the case of reactive arthritis [3]. The cases of rheumatoid arthritis and our case of spondyloarthritis developing before COVID-19 symptoms and in mild/asymptomatic patients suggest alternative mechanisms, such as immune-surveillance escaping. This ability of SARS-CoV-2 can be explained by disruption of the type I IFN-plasmacytoid dendritic cell response, which is the basis of the immune system activation, and the possible impairment of antigen recognition due to lymphocytopenia and exhaustion status of immune cells together with the down-modulation of the HLA-system induced by SARS-CoV-2. All of these mechanisms are

Fig. 1 Clinical manifestations of COVID-19-associated psoriatic arthritis



(A) Left knee arthritis: MRI showing synovial effusion in the left knee subquadricipital recess; suspected cutaneous psoriasis on the lumbar region. **(B)** Macroscopic inflammatory lesions of the caecum and rectum. **(C)** MRI showing sacroiliitis.

important in the development of autoimmune diseases. Interestingly, a cross-reaction between human and coronavirus proteins has been recently reported in dermatomyositis patients [8].

Acknowledgements

The authors wish to thank the patient for participating in the study.

Funding: No specific funding was received from any bodies in the public, commercial or not-for-profit sectors to carry out the work described in this article.

Disclosure statement: The authors have declared no conflicts of interest.

Data availability statement

Data are available upon reasonable request by any qualified researchers who engage in rigorous, independent scientific research, and will be provided following review and approval of a research proposal and Statistical Analysis Plan (SAP) and execution of a Data Sharing Agreement (DSA). All data relevant to the study are included in the article.

Lucia Novelli^{1,*}, Francesca Motta^{1,*}, Angela Ceribelli¹, Giacomo M. Guidelli¹, Nicoletta Luciano¹, Natasa Isailovic¹, Matteo Vecellio^{1,2}, Marta Caprioli¹, Nicola Clementi^{3,4}, Massimo Clementi^{3,4},

Nicasio Mancini^{3,4}, Carlo Selmi^{1,5} and Maria De Santis¹

¹*Rheumatology and Clinical Immunology, Humanitas Clinical and Research Center – IRCCS, Rozzano, Milan, Italy,* ²*Nuffield Department of Orthopaedics, Rheumatology and Musculoskeletal Sciences, Botnar Research Center, University of Oxford,* ³*Laboratory of Microbiology and Virology, Vita-Salute San Raffaele University, Milan, Italy,* ⁴*Laboratory of Microbiology and Virology, IRCCS San Raffaele Scientific Institute, Milan, Italy and* ⁵*Biomedical Science Department, Humanitas University, Pieve Emanuele, Milan, Italy*

Accepted 28 September 2020

Correspondence to Carlo Selmi, Humanitas University, Via Rita Levi Montalcini 4, 20089 Pieve Emanuele (MI), Italy.

E-mail: carlo.selmi@hunimed.eu

*Lucia Novelli and Francesca Motta contributed equally to this work.

References

- 1 Yokogawa N, Minematsu N, Katano H, Suzuki T. Case of acute arthritis following SARS-CoV-2 infection. *Ann Rheum Dis* 2020 (in press) doi: 10.1136/annrheumdis-2020-218281.
- 2 Saricaoglu EM, Hasanoglu I, Guner R. The first reactive arthritis case associated with COVID-19. *J Med Virol* 2020 (in press) doi: 10.1002/jmv.26296.
- 3 De Stefano L, Rossi S, Montecucco C, Bugatti S. Transient monoarthritis and psoriatic skin lesions following COVID-19. *Ann Rheum Dis* 2020 (in press) doi: 10.1136/annrheumdis-2020-218520.
- 4 Liew IY, Mak TM, Cui L, Vasoo S, Lim XR. A case of reactive arthritis secondary to coronavirus disease 2019 infection. *J Clin Rheumatol* 2020;26:233.
- 5 Ono K, Kishimoto M, Shimasaki T *et al.* Reactive arthritis after COVID-19 infection. *RMD Open* 2020;6:e001350.
- 6 Alivernini S, Cingolani A, Gessi M *et al.* Comparative analysis of synovial inflammation after SARS-CoV-2 infection. *Ann Rheum Dis* 2020 (in press) doi: 10.1136/annrheumdis-2020-218315.
- 7 Talarico R, Stagnaro C, Ferro F, Carli L, Mosca M. Symmetric peripheral polyarthritis developed during SARS-CoV-2 infection. *Lancet Rheumatol* 2020;2: e518–e519.
- 8 Megremis S, Walker TDJ, He X *et al.* Antibodies against immunogenic epitopes with high sequence identity to SARS-CoV-2 in patients with autoimmune dermatomyositis. *Ann Rheum Dis* 2020;79:1383–6.